

Clear Cell Sarcoma of the Foot: A Case Report of Malignant Melanoma of Soft Parts

by Al Kline, DPM¹.

Podiatry Internet Journal 2 (6):2

A case report is presented describing clear cell sarcoma of the foot (Malignant melanoma of soft parts). Melanoma is most commonly associated with pigmented lesions and nodules of the skin. Clear cell sarcoma (CCS) is an anaplastic tumor consisting of cells derived from melanoblasts not forming melanin in the skin, but rather mitotic changes more consistent with malignant melanoma in subcutaneous tissue, tendons and aponeurosis. The tumor is very rare and can pose clinical challenges in early diagnosis since the tumor lacks pigment and obvious color changes and can clinically appear as a benign, soft tissue tumor. A case report including surgical excision, histologic features and survival prognosis is presented.

Malignant melanoma is a relatively rare skin cancer accounting for only 4% of all skin cancers.¹ Clear cell sarcomas account for less than 1% of all melanomas. Clear cell sarcoma (CCS) is an indolent tumor of unknown histogenesis involving subcutaneous tissue, tendon and aponeurosis. CCS is a very rare, malignant soft tissue tumor and often called 'malignant melanoma of soft parts' due to the histologic similarities and lack of observable pigmentation often seen in cutaneous melanoma. It can affect all age ranges including children and young adults. The tumor is characterized by cytoplasmic melanosomes and melanotic mitotic figures isolated to the soft tissue without skin involvement. It presents as a soft tissue mass common to tendon and aponeurosis seen in the lower extremity, but can occur anywhere. It has also been reported to occur in other tissues such as the GI tract, kidney and retroperitoneum with clinical feature to that of malignant ovarian tumors.²

Interestingly, there is an increased incidence of lower extremity and foot CCS reported in the literature. It tends to present around the ankles and around the heel and aponeurosis of the plantar fascia. The tumor is rare with over 300 cases reported. Although the tumor is rare and histiogenically resembles melanoma, it resembles soft tissue sarcoma and has a high propensity to lymph node metastasis.³

Clear cell sarcomas pose a particular challenge in early detection. The tumor is more common in younger individuals, but can occur at any age. These lesions may start rather innocuously as a small, non-pigmented swelling and lay in-situ for many years.

Clear cell sarcomas may show a more rapid growth after laying in-situ. In particular, the border of the lesion may become irregular and progress with diameter enlargement. It is common to use the A,B,C,D,E criteria for early detection of malignant melanoma and this criteria may also be useful in the differential diagnosis of CCS. (Table 1) Early and late tumors may only reveal asymmetry and size changes.

Address correspondence to: 3130 South Alameda, Corpus Christi, Texas 78404.

¹Private practice in Corpus Christi, Texas. Email: al@kline.net

ABCDE Criteria in the diagnosis of MM

- A- Asymmetry to outline of the lesion
- B- Border irregularity
- C- Color variegation
- D- Diameter enlargement
- E- Evolving

Table 1 Clear cell sarcoma (CCS) often meets four of the five criteria of malignant melanoma with asymmetry, border irregularity, diameter enlargement and evolving changes of the tumor.

Case Report

A 61 year-old female presents with a painful, soft tissue tumor of the right medial heel. The tumor is irregular in shape, non-movable and firm to palpation. (Fig. 1). The tumor became bothersome in February 2007. She relates the tumor was present for 12 years and had remained small and non-painful. Over the past 2 years, she states it began to enlarge. There is no history of trauma. Further questioning revealed a history of previous nevi of the abdomen and neck. Multiple lesions had been biopsied in the past, but were negative for malignant transformation. She had a similar nodule on her neck. The patient had seen a dermatologist, who suggested watching the lesion. The differential diagnosis of the foot includes benign lipoma, dermoid tumor or cyst, dermatofibroma, fibroxanthoma, dermatofibrosarcoma, nodular fibroma, lipoblastoma and giant cell fibroblastoma.

It was decided to take the patient to surgery for excisional biopsy and removal of the tumor.

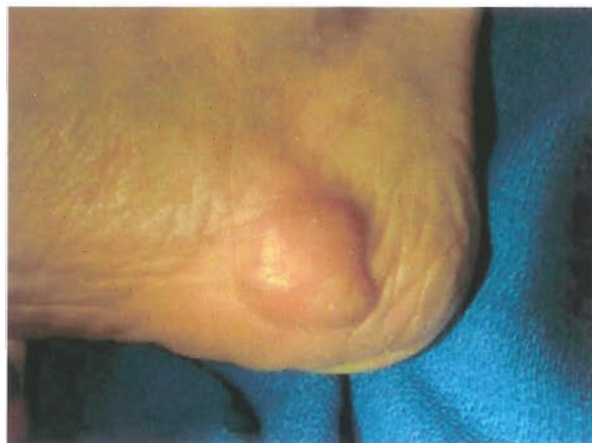

Figure 1 The lesion is irregular, firm and non-moveable. It is painful to palpation and measures about 2 cm in diameter.

Surgical Removal

The patient was brought to an out-patient operating facility and underwent local removal of the tumor. A curvilinear approach was planned to gain maximum exposure for removal of the tumor. During surgery, it was noted the tumor was nodular and adherent to the underlying epidermal tissue. Blunt dissection was used to remove the tumor. Redundant skin was sectioned and sent with the tumor to pathology for identification. (Fig. 2)

Histology Report

The specimen was designated "foot mass". The gross specimen measured 2.1 x 1.8 x 1.4-cm. (Fig. 3). The gross specimen was described as rubbery, yellow to pink-tan, fibrofatty soft tissue.

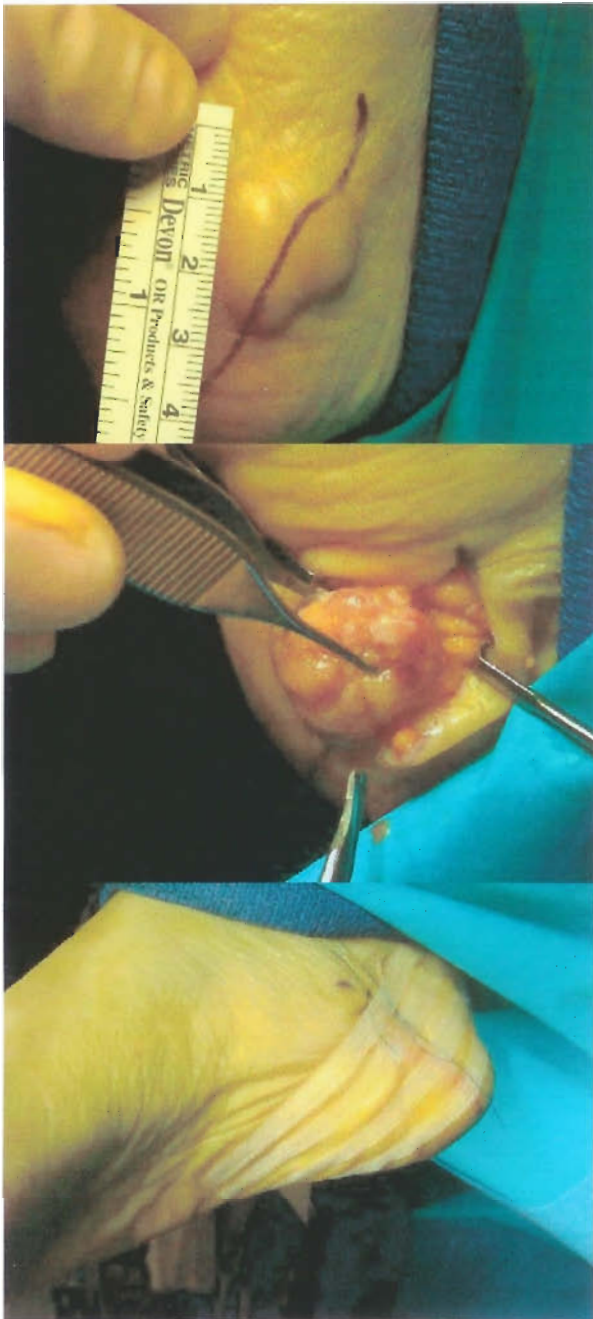


Figure 2 The tumor is nodular and adherent to the underlying epidermis extending through the dermis and subcutaneous fat.

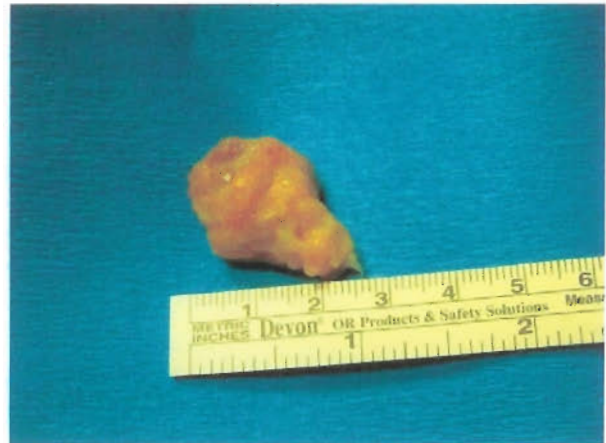

Figure 3 The tumor, once removed, is a firm, lobulated mass within subcutaneous fat measuring 2.1 x 1.8 x 1.4 cm.

The specimen is inked and serially sectioned to reveal an edematous, pink to red-tan lobulated mass with a variegated cut surface that measures about 1.5 x 1.4 x 1.2 cm.

Microscopic sections are stained routinely and underwent additional immunostains including Mart-1, CD10, HMB45, S-100, vimentin and pankeratin/cytokeratin. Routine stains show a malignant predominantly spindle cell neoplasm that diffusely infiltrates into and between connective tissue bundles and extends into adipose tissue. The neoplastic cells are arranged as vaguely cohesive aggregates which sometimes form ill-defined, loosely associated fascicles of variable size and thickness seen in various planes of section. Other fields show epithelioid-like clusters composed of smaller nests of spindle cells. Individual neoplastic cells contain oval to fusiform nuclei with prominent large macronucleoli. The nuclear to cytoplasm ratios are elevated. Mitotic figures are frequently encountered. The cytoplasm tends to be clear with some cells showing amphophilic cytoplasm. (Fig. 4)

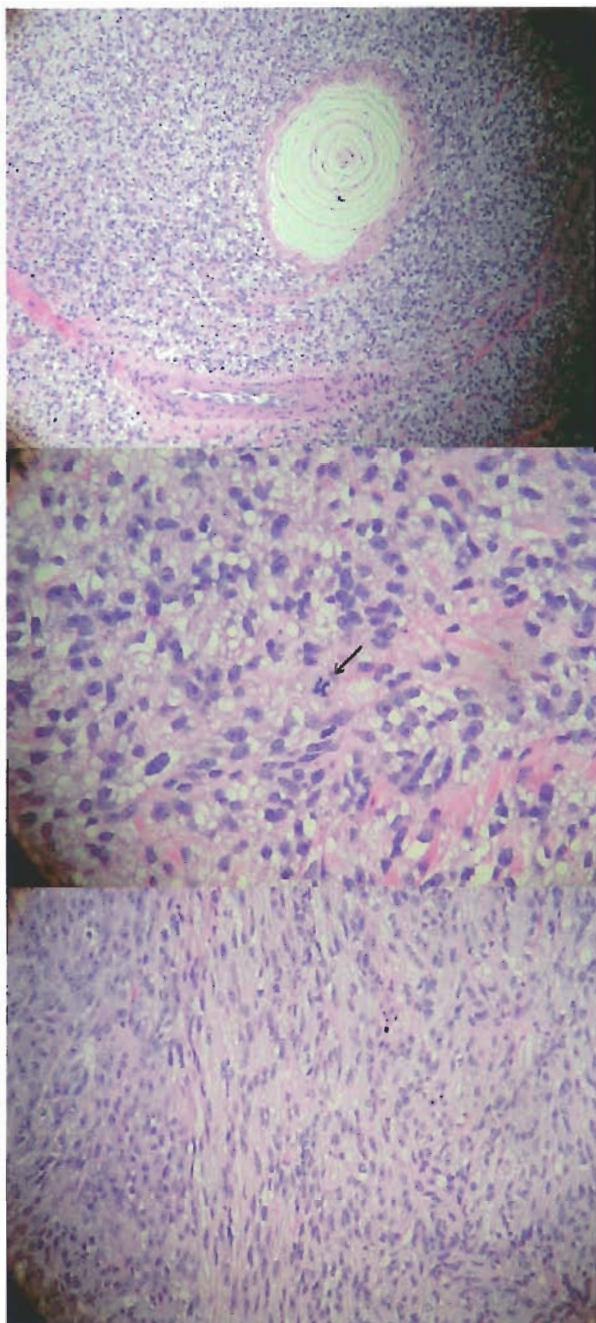


Figure 4 Under simple H&E (Hematoxylin–eosin) stains. Slide 1 in low power, reveals melanoma cells around a Pacinian corpuscle. Slide 2 in higher power, shows mitotic figures (arrow) in center with multiple, macronucleolus and fusiform nuclei within the tumor cells. Slide 3 reveals predominant spindle cells to the neoplasm. The cells are arranged as loose, cohesive aggregates and epithelioid like clusters of smaller nests of spindle cells.

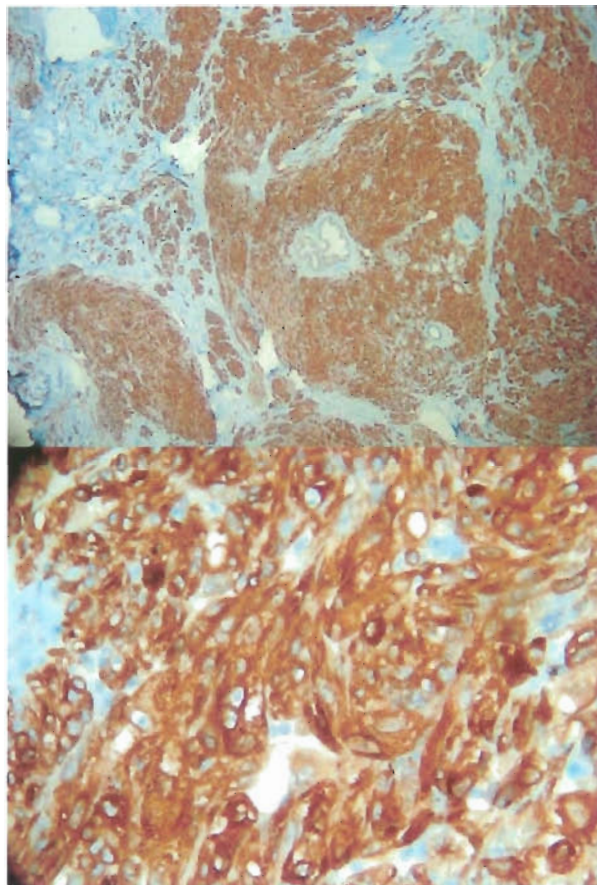


Figure 5 Immunoperoxidase stains using Mart-1 is highly specific for melanoma. Melan-A immunoperoxidase stains melanoma cells brown. The brown staining on these slides is considered positive for malignant melanoma.

The battery of immunostains is microscopically evaluated showing conspicuous positive reactions for Mart-1, HMB45, S-100 and vimentin. The pan cytokeratin is negative in the tumor cells with appropriate internal and external positive controls. The CD10 stain shows minimal, nonspecific cytoplasmic decoration. The Mart-1 immunostain uses peroxidase, which stains cancerous cells a brown color. This has been fairly specific for detection of malignant melanoma. (Fig. 5)

This case was deferred to M.D. Anderson Cancer Center of Houston and reviewed by Dr. Harry Evans. Submitted stains for S-100, MART-1 and HMB-45 were positive with negative keratin consistent with clear cell sarcoma. The t(12;22) chromosomal translocation was not reported.

Discussion

This case highlights the challenges of early detection of CCS. This is especially true of the foot. More troubling is the fact that the plantar aspect of the foot is often a common site for malignant melanoma.^{4,7} This tumor appears to have been in-situ for many years without radical growth before a more rapid increase in size and associated pain. Any recent change in a soft tissue nodule, change in symmetry of the tumor or any suspicious soft tissue mass along the ankle or foot may present clear cell sarcoma as a differential diagnosis.

There are now specific immunoreactive markers used to delineate clear cell sarcoma. More specifically, S-100 and HMB-45 are used to differentiate clear cell sarcoma from epithelial tumors, and more specifically, synovial sarcoma. Although the absence of keratin with positive S-100 and HMB-45 immunostains is often associated with the primary diagnosis of CCS, faint keratin immunoreactivity has been observed in clear cell sarcoma.

Therefore, keratin positivity does not rule out CCS.⁶ More recently, molecular genetic characterization of clear cell sarcoma has shown to be specific for t(12;22) chromosomal translocation which is typically not present in cutaneous malignant melanoma.⁵ However, the t(12;22) chromosomal translocation may not always be identifiable in some cases.

In 2002, a CCS was established from a metastatic tumor of a 17-year-old Japanese girl that originated in the left Achilles tendon. A small number of melanosomes were detected in the cytoplasm by electron microscopy. In this particular case, there was no t(12;22) chromosomal translocation identified although Melan-A and HMB-45 were reactive.⁸ As demonstrated by cytogenetics and reverse-transcriptase polymerase chain reaction, generally between 70 percent and over 90 percent of clear cell sarcomas have a t(12;22) translocation, fusing the EWS and ATF1 genes on chromosomes 22q12 and 12q13 respectively.⁹

Typically, once clear cell sarcoma is diagnosed, the patient will undergo CAT and PET scans. If there is a high suspicion of metastasis, sentinel lymph node biopsy (SLNB) is usually scheduled. Lymph node metastasis has been reported in a high number of cases, so sentinel lymph node biopsy is now indicated with the diagnosis of CCS.⁶

Recently published data suggests that baseline laboratory testing such as LDH, liver function studies and imaging studies such as chest x-rays, CT, MRI, PET and bone scanning is not typically beneficial in early stage melanomas without signs or symptoms of metastasis. However, LDH have been incorporated into the AJCC 2002 melanoma staging guidelines for the classification of stage IV or distant disease. Elevated LDH levels are associated with the worst prognosis and survival in this subgroup.¹

In this particular case, the tumor was initially excised and a larger margin of tissue will need to be removed. This will likely include wide excision with split thickness skin grafting. Sentinel node biopsy is highly recommended in all cases of diagnosed CCS due to the propensity of lymph node metastasis.

Survival

In general, CCS has a high propensity of lymph node metastasis and the prognosis is dismal once metastasis occurs. However, it does appear from multiple literature reviews, that tumors less than 2 cm have a generally better long term prognosis.

Deenik, et al, reviewed 30 cases of clear cell sarcoma which revealed a 5 year survival rate of 54 per cent in 29 patients. Unfortunately, when the sentinel node biopsy is positive, distant metastasis appeared within 2 years, even after radical lymph node dissection in all cases. Chemotherapy has not had an appreciable effect on CCS, but remarkable responses to interferon α -2b have been reported.^{6,7} In this same study, 7 of 14 patients with tumors greater than 2cm had a 50 percent survival rate.⁶

In another study, Sara, et al, reported both survival and distant metastasis were correlated with tumor size (P value less than 0.01 for patients with tumors greater than or equal to 5 cm versus less than 5 cm) in 17 cases. Other clinical and pathologic factors had no significant relation to survival or distant metastasis when tumor size was greater than 5 cm.⁷

A Mayo Clinic study of 35 cases showed tumor size and the presence of necrosis as statistically significant predictors of prognosis. 12 patients with tumors measuring over 5 cm were either living with the disease or died. 11 of 20 patients with tumors measuring less than 5 cm were alive with no evidence of disease.

Tumor necrosis was present in 10 cases; 8 of these patients died of disease and one was alive with disseminated metastases.¹⁰

Although there have been reports of poor response with chemotherapy, there has also been reports of amputation of the diseased limb, even in the presence of metastasis. In 1983, Eckardt reported 27 patients ranging in age from 9 to 57 years and were followed an average of 7 years. Females outnumbered males by 2 to 1 and the distal extremity location predominated. At presentation, the tumor was localized in 21 patients, regionally metastatic in 5, and disseminated in 1. Surgery was the primary therapy for 26 patients and adjuvant treatment was nonstandardized. Its effectiveness is undetermined. Local recurrence developed in 10 patients, regional metastases in 9, and widespread dissemination in 12. Twelve patients died of the disease from 7 months to 10 years after diagnosis and only 11 patients remained free of disease. They reported that wide excision, or perhaps even radical excision or amputation, is the surgical treatment of choice.¹¹

Conclusion

This case describes a solitary, subcutaneous lesion that histologically represents clear cell sarcoma or malignant melanoma of soft parts. The diameter of this tumor is over 2cm and less than 5 cm. However, more aggressive resection of tissue and lymph node biopsy is required to map the tumor margins and rule out metastasis. This patient had previous naevi and a similar nodule located on the neck that may reveal other malignancy. This patient is presently under further investigation and testing for primary sources of the tumor and evidence of metastasis. At the time of this writing, the PET and CAT scans were negative, so the overall, long-term prognosis is promising.

References

1. Swetter, S.M., et al: Malignant Melanoma. Emedicine online [[online](#)].
2. Katabuchi, H, et al: Clear cell sarcoma arising in the retroperitoneum. In J Gynecol Cancer: 12(1): 124-127, Jan-Feb, 2002.
3. Finley, et al: Clear cell sarcoma: the Roswell Park experience: Journal of Surgical Oncology, 77(1):16-20, May,2001.
4. Fortin, PT, et al. Malignant melanoma of the foot and ankle. JBJS (Am), 77:1396-1403, 1995. [[PDF](#)]
5. Fujimura, Y., et al: The EWS-ATF-1 gene involved in malignant melanoma of soft parts with t(12;22) chromosome translocation, encodes a constitutive transcriptional activator. Oncogene 12: 159-167, 1996.
6. Deenik, W. et al: Clear cell sarcoma (malignant melanoma) of soft parts: A clinicopathologic study of 30 cases. Cancer 86(6): 969-975, Sept. 1999.
7. Sara, AS, et al: Malignant melanoma of soft parts (clear cell sarcoma). A study of 17 cases, with emphasis on prognostic factors. Cancer, 65 (2): 367-374, Jan. 1990.
8. Moritake, H. et al: Newly established clear cell carcinoma (malignant melanoma of soft parts) cell line expression melanoma-associated Melan-A antigen and overexpressing C-MYC oncogene. Cancer Genet Cytogenet, 135(1):48-56, May, 2002.
9. Patel, RM, et al: Dual-color, break-apart fluorescence in situ hybridization for EWS gene rearrangement distinguishes clear cell sarcoma of soft tissue from malignant melanoma. Mod Pathol. 18(12):1585-1590, Dec., 2005.
10. Lucas, et al: Clear cell sarcoma of soft tissues. Mayo Clinic experience with 35 cases. Am J Surg Pathol: 16(12): 1197-1204, Dec., 1992.
11. Eckardt, JJ, et al. Clear cell sarcoma. A clinicopathologic study of 27 cases. Cancer. 52(8): 1482-1488, October, 1983.

Special thanks to Kenneth Linville, MD and Michael Bailey, MD in preparing the slides.